

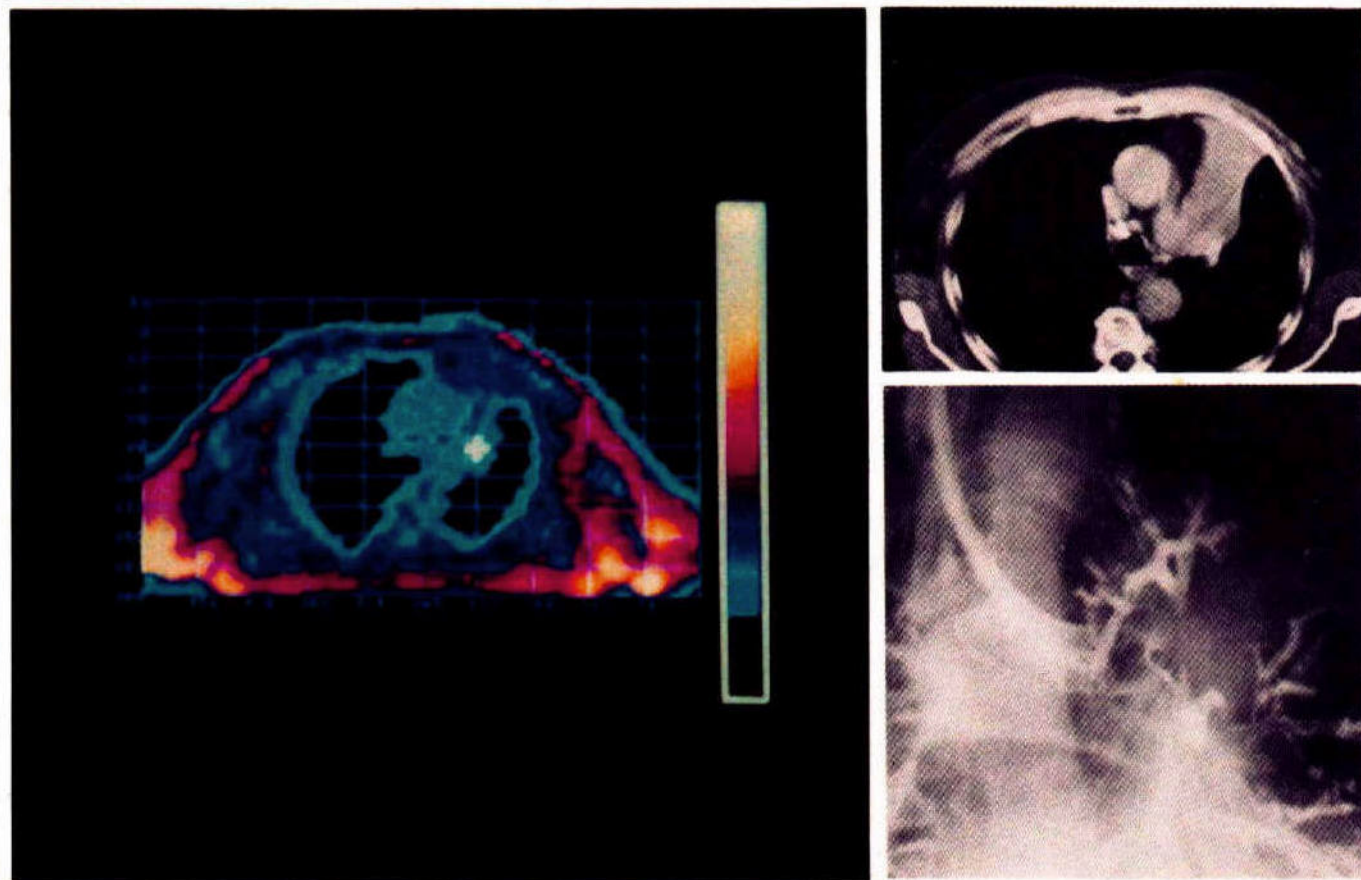
RADIOLOGY NUCLEAR MEDICINE MAGAZINE

JUNE 1981

*Including...
Computed Tomography and Ultrasound*

NMR clinical trials begin . . .

see page 8



Above: Transverse thorax image by nuclear magnetic resonance performed at the office of **Drs. Ross, Lie, Thompson & Associates** in Cleveland. Upper Right: This CT scan of the same patient was made immediately preceding the NMR examination. Middle Right: Bronchogram of the same patient.

Diagnosis: Proven carcinoma of the left upper lobe with peripheral consolidation.

First clinical trials of diagnostic NMR

Clinical trials of the Fonar QED 80 nuclear magnetic resonance scanner are being conducted by Drs. Ross, Lie, Thompson & Associates, a radiology group in private practice in the Cleveland area. NMR studies are being correlated with computed tomography, ultrasound and general radiological procedures.

THE FIRST continuing clinical trials of a nuclear magnetic resonance diagnostic system began late in January, 1981, in a private radiology practice in the Cleveland area. The Fonar QED 80 NMR unit, developed by Raymond Damadian, M.D., is now being used at a new Diagnostic Center by Drs. Ross, Lie, Thompson & Associates in Mayfield Heights, Ohio.

The Diagnostic Center, one of several facilities owned by this radiology group in the three-county suburban area southeast of Cleveland, was designed to provide one of the most complete private practice diagnostic imaging centers in the world. NMR studies are correlated with computed tomography, ultrasound, and conventional radiological procedures. The four million dollar facility is equipped with a new General Electric CT/T 8800 whole body CT scanner and a recently installed Diasonics RA-1 sector scan real-time ultrasound system, in addition to the NMR unit.

Ronald J. Ross, M.D., senior member of the group, explained: "We have accepted the challenges of the rapidly advancing technology in our field and wish to do our share in the development of new modalities for the improvement of diagnosis and medical care. This is challenging and exciting, not only for those in academic settings, but also for those of us in private practice."

Dr. Ross indicated that radiology is the logical medical

specialty to be involved in the development and clinical use of NMR.

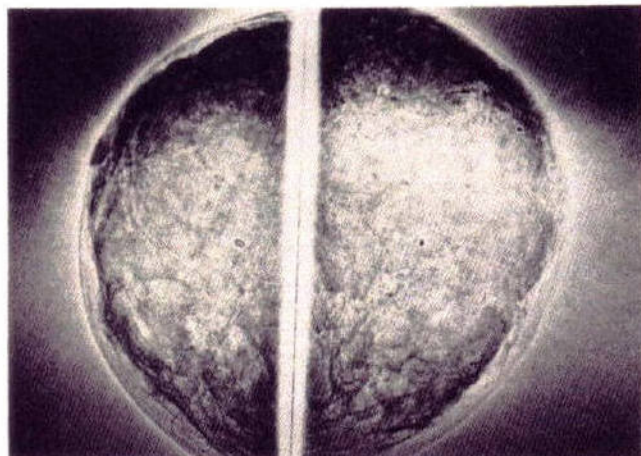
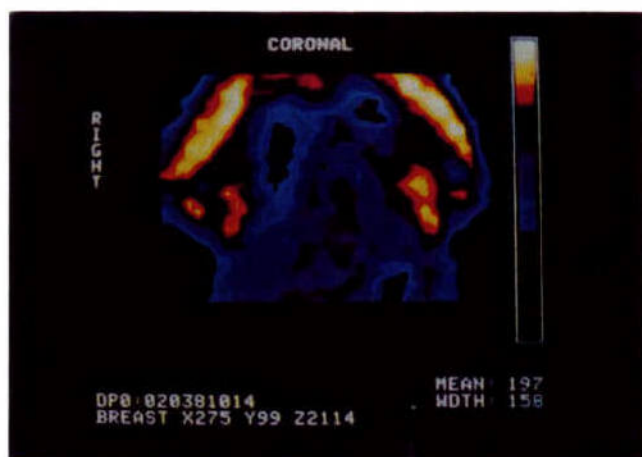
Radiologists and NMR

"From the time we enter our radiology residency," he said, "we are physicians working with images and other information provided by large and expensive equipment. We are trained to utilize the appropriate imaging modality in order to provide the clinician with the desired information.

"Furthermore, we are accustomed to the large expenditures required to acquire and finance diagnostic imaging equipment, which can range from an R/F unit for routine use at \$150,000 to \$200,000, to the CT system we installed in September which represents an investment of approximately \$1.7 million financed over the life span of the equipment." The Fonar QED 80 costs \$550,000.


Drs. Ross, Lie, Thompson & Associates have been in the forefront of new radiologic technologies. In 1975, they were the first in the world to install a head and body CT scanner in a private practice office.* It was the second CT unit of any type in northeastern Ohio. (See

*This system, an Ohio-Nuclear/Technicare DeltaScan 50, is being given to the Vellore Medical College in Vellore, India.



Left: A six millimeter coronal breast section image by nuclear magnetic resonance. Right: Xeroradiogram of the same patient. Diagnosis: mammary dysplasia with no evidence of malignancy.

Ronald J. Ross, M.D., senior member of Ross, Lie, Thompson & Associates, is seen on the right with the Fonar QED 80 NMR scanner, and below at the Fonar diagnostic console which demonstrates both proton map images, and T_1 spin lattice relaxation time measurements for tissue chemistry evaluation.



RADIOLOGY/NUCLEAR MEDICINE MAGAZINE, March/April, 1978.) They have since performed more than 20,000 CT examinations.

The group was the first private practice office in the Greater Cleveland area to install an ultrasound B-scanner with gray-scale, and among the first in the country to use the Xerg low-dose mammographic system.

Dr. Ross became interested in NMR imaging after Dr. Damadian addressed the alumni association of the Albert Einstein College of Medicine. Dr. Damadian and Dr. Ross are members of the class of 1960.

"We communicated regularly," Dr. Ross explained. "In 1978, I visited Dr. Damadian's facility in New York where he was doing research in NMR. At that time it was mutually agreed that Dr. Damadian would sell his first commercial system to our radiology group and install it for clinical trials in one of our offices in Cleveland."

Call it "Magnetic Resonance Imaging"?

Dr. Ross prefers the term "Magnetic Resonance Imaging" (MRI) rather than nuclear magnetic resonance to underline the fact that it does not involve nuclear medicine radioisotopes, and to avoid the possible controversial connotations of the word "nuclear" as it relates to power generation and weapons. [However, to avoid confusion, we will continue to use the NMR term.—Ed.]

He sees NMR as a complementary diagnostic modality rather than a primary one, and insists that it should not be considered a replacement for, or competitive with, any current technologies.

"NMR is a noninvasive modality that requires no x-ray or radioactive materials, and thus offers a fascinating potential alternative to current imaging techniques for the diagnosis of pathologic entities.

"In the current literature, there are no reports of actual or predictable sequelae from magnetic fields and radio-frequency at the level used for in vivo studies during clinical NMR examination time.

"NMR offers unique possibilities for visual imaging, demonstration, localization and interpretation of normal

and pathologic structures throughout the body," Dr. Ross said.

He points out that NMR must be understood in the context of first generation state of the art. "For example, NMR images we are producing today are superior to those produced by the first generation CT scanners in 1972-1973.

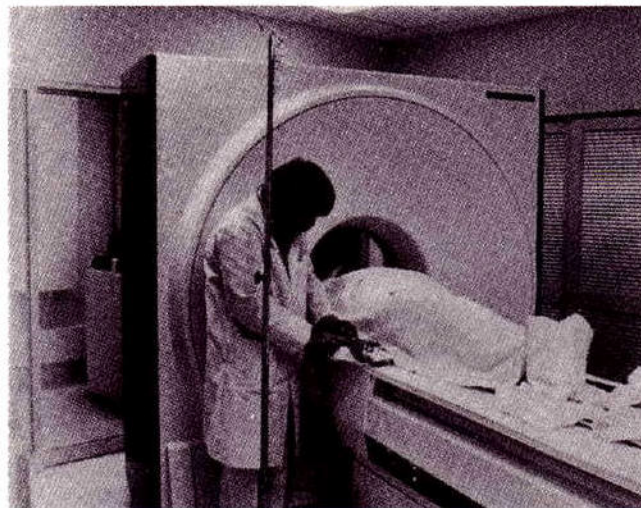
"The estimated resolution of the Fonar QED 80 is six millimeters. There has been significant improvement in resolution since Damadian published his first tumor images in 1976.

"Thus it is reasonable to expect improvement with further development of data acquisition technology and data processing hardware and software.

"However, within the next few years I do not expect NMR to provide an image that will show the adrenal glands, a herniated intervertebral disk, or an 8 millimeter microadenoma of the pituitary gland as we are demonstrating with our CT system.

"Nevertheless, the NMR studies we are now performing demonstrate its potential to assess tissue pathology by means of measurements relating to tissue chemistry.

"This view is supported," Dr. Ross said, "by useful in vitro and small animal in vivo studies by NMR of sickle



Right: The new General Electric CT/T 8800 computed tomography scanner at the Diagnostic Center is located near the NMR unit to facilitate correlative studies using both modalities. Behind the glass doors at the left rear is an environmentally controlled room for the 8800 and Fonar computers, with its own air conditioning and humidity control equipment.

cell anemia, hyponatremia, cerebral edema, myocardial ischemia, hepatic ischemia, renal ischemia, cerebral ischemia, pulmonary edema, amniotic fluid, and blood flow.

"I must emphasize that conclusions about NMR must await the results of clinical trials at other centers as well as our own. Our data will be correlated with findings at other centers that are now also beginning clinical studies. We will be presenting our data at conferences and in appropriate clinical journals."

Other clinical trials

It is reported that trials have begun or are imminent at Nottingham University in England and at Aberdeen Royal Infirmary at the University of Aberdeen in Scotland. A Fonar QED 80 is being installed at the University of Mexico in Monterey and clinical trials are expected within a few months. A clinical prototype NMR unit has been installed at the University of California in San Francisco.

In the meantime, laboratory work with experimental NMR systems has been continuing at a number of institutions in the U.S. and abroad.

"NMR is developing in many research centers," Dr. Ross points out. "Just as NMR won the Nobel Prize in biochemistry several years ago and the developers of the CT scanner were awarded the Nobel in 1979, I believe it is very possible that in five years, diagnostic in vivo NMR will be worthy of consideration for the Nobel Prize for its application in medicine."

By the end of March, about 20 patients had participated in NMR clinical protocols and useful images and T_1 tissue chemistry data have been obtained.

The purpose of the clinical trials is to acquire baseline information. Physiochemical and anatomic evaluation of both normal and pathologic entities by NMR are correlated with CT, ultrasound, nuclear medicine and

radiographic images, as well as with biopsies and surgical findings where possible.

The established imaging modalities are also used to localize the region of interest for study by NMR. Fixed anatomical landmarks, such as the suprasternal notch, the iliac crest and the symphysis pubis, are used, and localization is coordinated with the NMR scanner's laser light positioning system.

"Since the publication of *Tumor Detection by Nuclear Magnetic Resonance* by Damadian (*Science*, March 19, 1971; pp. 1151-1153), many investigators have been able to use NMR to discriminate between benign and malignant structures in vitro, including tissues of the breast, skin, gastrointestinal tract, liver, spleen, lymphatic structures and bone," Dr. Ross said. "This suggests that NMR tissue chemistry procedures in vivo will provide significant advances in the evaluation of tissue pathology."

Clinical protocols

One of the clinical protocols is to evaluate normal and abnormal breasts, particularly to determine the T_1 values for normal, dysplasia, and the breast with a malignancy.

"There is need for an additional modality for breast evaluation," Dr. Ross said. "Currently, mammography is the best available diagnostic modality for early detection of breast cancer. I have been performing mammography since 1962, but after interpreting thousands of mammograms I am convinced that it should not be considered the ultimate diagnostic technique.

"There is significant difficulty in interpreting the mammograms of patients with extensive mammary dysplasia, where there is severe fibrocystic disease and very little fatty replacement. It is difficult to definitively identify malignant lesions in this type of breast by palpation.


"Although the NMR proton images of the breast may not be as explicit as a mammogram, the T_1 analysis of tissue chemistry may be more revealing and provide a definitive diagnosis. Noninvasive and risk-free NMR may develop into a viable screening modality for breast cancer."

Another protocol is directed toward correlation of NMR images and T_1 data with CT scans of normal and abnormal structures of the kidneys, pancreatic area, uterus, liver, etc.

"Obviously the information provided by CT and NMR is different," Jay S. Thompson, M.D., a member of the group, remarked, "but they complement each other. Anatomically, we can see a mass quite easily on CT. It is more difficult to accurately demonstrate the structure in question with NMR, but NMR's ability to measure the T_1 values may provide a much more accurate way of judging between benign and malignant processes, perhaps the most definitive other than tissue biopsy."

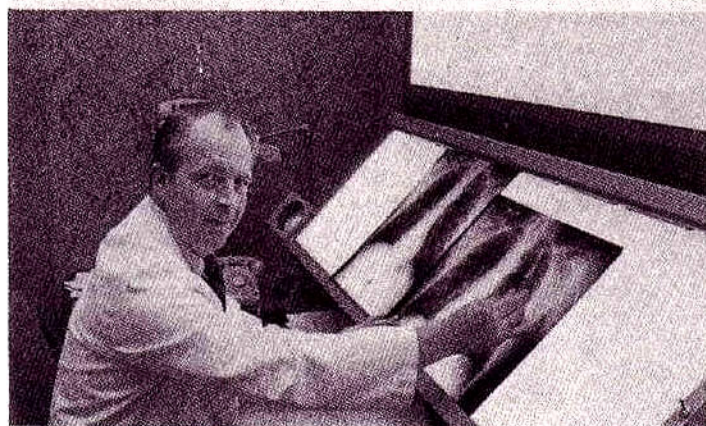

Patients are examined with the NMR unit after obtaining the permission of the referring physician. Members of the group discuss with the clinician the capabilities of NMR and explain that it is noninvasive. In explaining the procedure to the patient, it is pointed out that there is no discomfort or risk. The machine is so quiet that the patient tends to fall asleep. (There are no moving parts except for the patient bed.)

It is expected that the group's large volume of CT and ultrasound examinations will produce a substantial number of NMR studies.



Another key instrument at the Diagnostic Center for the correlation of NMR studies with other imaging modalities is the Diasonics RA-1 sector scan real-time ultrasound system.

An addition to Dr. Ross, members of the private practice radiology group of Ross, Lie, Thompson & Associates include Sutek Lie, M.D., right; Jay S. Thompson, M.D., below; and Kyung Kim, M.D., lower right. Not pictured is Ronald A. Bailey, M.D.



The Fonar installation

The Fonar QED 80 weighs 20,000 pounds. The gantry is 17 feet wide and the scanning table is 18 feet long. The magnetic field is 450 gauss and the radiofrequency is 1.75 megahertz.

To prevent extraneous radiofrequency and electromagnetic interference from disturbing the diagnostic process, a uniquely designed room was required to provide the necessary environment. The walls, ceiling, floor and door are specially constructed to eliminate external interference.

The heat of the magnet is controlled electronically and its temperature automatically recorded. Any radical change in the magnet temperature could affect the electromagnetic field.

The radiofrequency coil within the rectangular patient aperture provides the RF pulse and is also the receiver of the NMR signal. This information is processed by the computer and demonstrated on a CRT on the system console as a proton map image and also as numerical data for T_1 (spin lattice relaxation time). Color-coded images are produced by a Ramtek computer-controlled color graphics system.

The Fonar utilizes a Data General Nova 3 computer. The computer and magnet power supply produce 32,000 BTU, and for computer stabilization this equipment is placed in a separate environmentally controlled room with its own air conditioning and humidity control.

The CT computer is also housed in this computer room, which is separated from the CT gantry area by

sliding glass doors. Servicing is facilitated by mounting the equipment modules on rollers so they can easily be pulled out for access.

The Fonar control console is located in the adjoining master control room, and a closed circuit TV camera monitors the portions of the patient not visible through a window. The operator's console for the CT scanner, which is in an adjacent room on the other side, is also located in this master control room.

A direct telephone link to Fonar Corporation has been installed that enables the technician to transmit images and tissue data directly from the console in Cleveland to CRT monitors in the Fonar office in Melville, N.Y. Also being completed is a telephone link that will enable Fonar engineers to diagnose and correct malfunctions in the electronic and computer systems.

Clinical NMR with the Fonar system

Ten minutes is required for one complete axial section of the chest or abdomen, and two contiguous slices are obtained in 20 minutes. A smaller structure, such as a breast, can be scanned in significantly less time. Six to eight minutes are needed to obtain a T_1 measurement in any specific area.

The Fonar ("Focused NMR") is a focused field system which can perform a true T_1 in a designated site. The cursor is placed over the region of interest and the direct measurement obtained is specific for this focus of tissue. The T_1 values are not the result of software manipulation and back projection reconstruction techniques as in CT

scanning.

Dr. Thompson explained that it is important to know precisely where the measurement is made.

"We had one case in which the patient had a large solid tumor of the kidney. The tumor was growing on the surface, but the center was necrotic having outstripped its vascular supply. The T_1 value in the center of the necrotic tissue was different from the measurement at the periphery where there were actively growing cancer cells."

The Fonar method makes possible direct re-scan and visual enlargement of any region of interest without computer reconstruction. Unlike CT enlargements, based on software manipulation with possible image degradation, the Fonar can produce an enlargement of the structure that contains more information than the original scan.

The Cleveland group currently is working with hydrogen since the hydrogen nucleus is the most abundant in living tissue, and the proton produces a comparatively strong signal in vivo to produce good images by proton mapping. They also are performing T_1 (spin lattice relaxation time) measurements. Dr. Ross indicated that perhaps in the future they will be able to evaluate other elements, such as phosphorus and sodium and determine T_2 (spin-spin relaxation time) values.

The radiology group

Drs. Ross, Lie, Thompson & Associates is a private practice radiology group consisting of five full-time radiologists and two consulting radiologists. Full-time members are Ronald J. Ross, M.D.; Sutek Lie, M.D.; Jay S. Thompson, M.D.; Kyung Kim, M.D.; and Ronald A. Bailey, M.D. The group is an outgrowth of a radiology practice that was established in 1956 by Maurice D. Sachs, M.D., who is now a consultant. He was joined by Dr. Ross in 1965.

The practice is conducted primarily at three fully-equipped and staffed office locations and at the Community Hospital of Bedford, Ohio.

One facility, which has been in operation for a number of years, is a large general radiology suite in Hillcrest Medical Building No. 1 in Mayfield Heights, Ohio, across from a major community hospital. Conventional radiographic and fluoroscopic procedures of all kinds are performed. Down the hall, with a separate entrance to provide privacy, is the mammography section. It is equipped with a Xerg low-dose electron radiography unit from Xonics Medical Systems. (See page 70.)

The new Diagnostic Center where the NMR unit is located is on the ground floor of Hillcrest Medical Building No. 2, a connecting twin structure. The NMR facility has been visited by physicians, researchers and others from all over the U.S., and from many other countries including Canada, Sweden, Italy, Japan and the Peoples Republic of China.

The Diagnostic Center has its own ambulance entrance with space for two vehicles. The ambulances back up under a canopy and the stretcher is wheeled directly into the diagnostic suite, by-passing the waiting room.

The third office facility is located in the Parkway Medical Center in Beachwood, Ohio, a few miles away. General radiographic examinations are performed, including mammography with a Xeroradiography unit, as well as ultrasonography. Thus, between the two facilities, a choice of mammographic techniques is offered.

Nuclear medicine procedures are conducted at the Community Hospital of Bedford, where a new gamma camera has been installed. An ultrasound unit also recently has been acquired at Bedford.

Each radiology suite is equipped with emergency resuscitative equipment, including a cardiac monitor, defibrillator and respirator. An alarm button elicits an immediate response by the radiologists and technical staff, all of whom are trained in cardiopulmonary resuscitative procedures. One of the staff members at the Diagnostic Center is also an emergency medical technologist paramedic (EMTP). Referring physicians in the building respond immediately when additional emergency consultation and treatment for patients is needed.

The group also serves two smaller facilities, one in Cleveland Heights and another in an industrial medicine center in Solon, Ohio.

In addition, they have a portable x-ray unit (Porta Ray) which is used to obtain radiographs in a home, nursing center or other remote site when required.

These various diagnostic services are provided to about 300 physicians and 15 hospitals in the area.

The Diagnostic Center CT department in Mayfield Heights is directed by Dr. Lie from the off-line physician's terminal of the CT/T 8800. It is equipped with a communications system that links all areas of the ground floor unit and also the general diagnostic radiology suite.

Approximately 500 CT examinations are performed each month on the GE CT/T 8800. This volume is achieved by operating two shifts a day, with a radiologist and a full complement of technologists on each shift.

About 55 percent of the CT exams are of the brain; and 35 percent are body examinations, including chest, abdomen, pelvis and some extremities. Ten percent of the CT examinations consist of the new spinal CT technique, especially for herniated disks and also for trauma and postoperative evaluation.

All members of the group work in all areas of radiology and, in addition, each also has one or more areas of special expertise.

Dr. Lie has a sub-specialty in arthrography and special procedures. His most recent publication in that field deals with the injection of the bursae of the shoulder. Dr. Kim has a special interest in computed tomography and ultrasound.

Dr. Thompson was trained in pediatric radiology and spends the larger portion of his time at the Parkway Medical Center office which has a special pediatric room and where a number of pediatricians have their offices.

Dr. Ross has had extensive experience in cranial CT and was one of the first to describe the CT changes in patients with multiple sclerosis. He has published many scientific papers, and is now devoting considerable time to research and writing in the field of NMR. He has authored chapters on nuclear magnetic resonance in *Merrill's Atlas of Roentgenographic Positions and Standard Radiologic Procedures* to be published by C. V. Mosby Co., and in *Nuclear Magnetic Resonance Imaging* to be published by W. B. Saunders Co. Dr. Ross has presented many lectures on clinical NMR in the U.S., including the 1980 RSNA meeting in Dallas. He recently lectured on NMR at several medical centers in Italy.

EDITOR'S NOTE: For more information about the Fonar QED 80 NMR scanner, contact Fonar Corporation, 110 Marcus Drive, Melville, NY 11734; Tel. 516/349-9260, or circle No. 501 on the Reader Service Card.